



Clinical Notes

The ultrasound-guided superficial cervical plexus block for anesthesia and analgesia in emergency care settings^{☆,☆☆}

Andrew A. Herring MD^{a,*}, Michael B. Stone MD, RDMS^{a,b}, Oron Frenkel MD^a,
 Annie Chipman MD^a, Arun D. Nagdev MD^{a,b}

^aDepartment of Emergency Medicine/Alameda County Medical Center, Highland General Hospital, Oakland CA, USA

^bUniversity of California, San Francisco CA, USA

Received 10 June 2011; accepted 21 June 2011

Abstract The ultrasound-guided superficial cervical plexus (SCP) block may be useful for providers in emergency care settings who care for patients with injuries to the ear, neck, and clavicular region, including clavicle fractures and acromioclavicular dislocations. The SCP originates from the anterior rami of the C1–C4 spinal nerves and gives rise to 4 terminal branches—greater auricular, lesser occipital, transverse cervical, and suprascapular nerves—that provide sensory innervation to the skin and superficial structures of the anterolateral neck and sections of the ear and shoulder. Here we describe an ultrasound-guided technique for blockade of the SCP that is potentially well suited to emergency care settings. We present the first case description of its successful use to manage pain for a patient with an acute clavicle fracture. This case is presented to highlight one of several potential applications of this promising new technique in the emergency department.

© 2011 Published by Elsevier Inc.

1. Introduction

The superficial cervical plexus (SCP) originates from the anterior rami of the C1–C4 spinal nerves and gives rise to 4 terminal branches—greater auricular, lesser occipital, transverse cervical, and suprascapular nerves—that provide sensory innervation to the skin and superficial structures of the anterolateral neck and sections of the ear and shoulder [1,2]. All 4 of these branches emerge at the posterior border of the sternocleidomastoid (SCM) muscle at the level of the superior pole of the thyroid cartilage (Fig. 1). Importantly,

SCP innervation includes commonly injured structures including the auricle of the ear, the acromioclavicular joint, and the clavicle [3–8]. The greater auricular nerve (C2 and C3) is the largest branch of the SCP; it travels around the posterior border of the SCM and splits into posterior and anterior divisions that innervate the anterior and posterior portions of the auricle. The lesser occipital nerve (C2 and C3) ascends cephalad to supply the skin of the superior posterior neck and scalp behind the auricle. The transverse cervical nerve (C2 and C3) travels laterally toward midline to supply the anterolateral aspect of the neck from the sternum to the mandible. The supraclavicular nerve (C3 and C4) travels caudad in the posterior triangle of the neck beneath the platysma and splits into 3 branches that supply the “cape” of the neck and shoulder to the level of the second intercostal space including the clavicle and the sternoclavicular and acromioclavicular joints [9]. The distribution of cutaneous innervation is illustrated in Fig. 2.

[☆] Prior presentations: None.

^{☆☆} Funding sources: None.

* Corresponding author. Department of Emergency Medicine, Highland General Hospital, Oakland, CA 94602-1018, USA. Tel.: +1 510 437 8497; fax: +1 510 437 8322.

E-mail address: aherring@acmedctr.org (A.A. Herring).

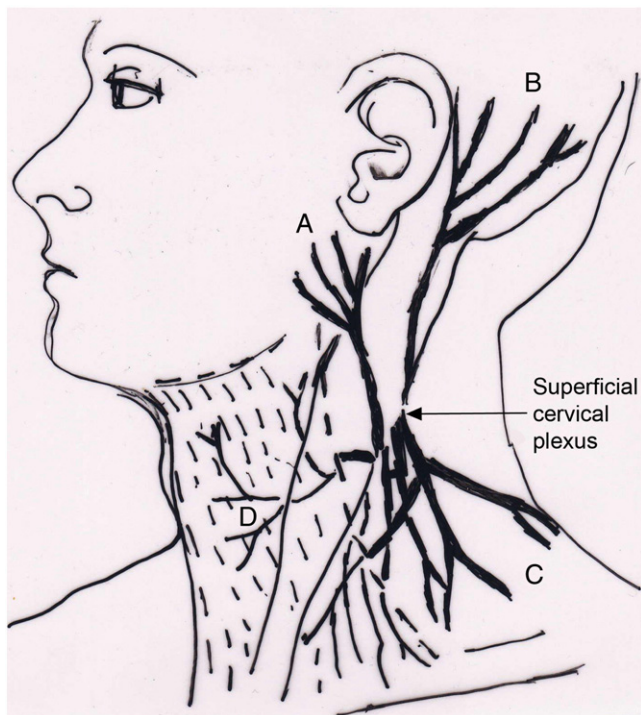


Fig. 1 The SCP emerges from the posterior lateral border of the SCM muscle innervating the anterolateral neck and superior and posterior aspects or “cape” of the shoulder. The 4 terminal branches of the SCP are illustrated here: A, greater auricular nerve; B, lesser occipital nerve; C, suprascapular nerve; and D, the transverse cervical nerve. Figure drawn by Diana Herring based on Fig. 17-2 from Morgan GE, Mikhail MS, Murray MJ, *Clinical Anesthesiology*, 4th Edition, 2006.

2. Ultrasound-guided nerve block technique

2.1. Preparation

Standard precautions for the performance of ultrasound-guided nerve blocks should be followed. This includes performing the block on awake and alert patients with continuous cardiac monitoring. The operator should be familiar with the signs of local anesthetic systemic toxicity and its management. The skin overlying the injection site should be free of signs of infection and prepped with an antiseptic solution. The probe surface in contact with the skin should be covered with a sterile adhesive dressing (Table 1).

2.2. Survey scan

The SCP is located by placing a high-frequency linear transducer at the posterior border of the SCM muscle at the level of the superior pole of the thyroid cartilage. Here the SCP is surrounded by hyperechoic fascia posterior to the SCM, and it can be difficult to identify the individual nerves. The greater auricular nerve is a useful landmark reliably identified as a small hypoechoic round structure just

superficial to the SCM (Fig. 2). The levator scapulae muscle (LSM) and carotid artery should be identified; apply color Doppler to assess for other vessels.

2.3. Positioning

If well tolerated by the patient, lateral decubitus position with the target side facing up is optimal. The ultrasound machine is then positioned across from the patient allowing an unobstructed view of the ultrasound display screen to optimize block ergonomics (Fig. 3).

2.4. Needle insertion and local anesthetic injection

Although both anterior in-plane (parallel to the transducer axis) and out-of-plane (perpendicular to the transducer axis) approaches have been described, we prefer the posterior in-plane approach to the SCP. In this technique, the transducer is placed in a transverse orientation across the neck with the probe marker facing medial (toward the thyroid cartilage). The needle is then inserted at the posterior border of the SCM at the level of the cricoid cartilage and advanced underneath the muscle belly toward the carotid artery. The needle tip is positioned to inject local anesthetic deep to the SCM along its tapering posterolateral border but superficial to the prevertebral fascia. Deeper injection should be avoided because it can result in a deep cervical plexus block (Fig. 4). As much as 15 mL of local anesthetic is typically used for this block, although with very accurate placement, as little as 2 mL can be successful [5,10].

2.5. Disposition

Any patient admitted to the hospital should have clear documentation of the procedure including time of block placement to avoid confusion by subsequent providers examining the patient. It is our practice to mark the clavicle that has been blocked with pen in addition to chart documentation. This is particularly important for undifferentiated trauma patients who may receive care by multiple consultants. Patients suitable for discharge should be observed for 1 hour postprocedure and released with easy-to-understand information about the procedure and complication warning signs.

3. Case description

A 20-year-old left-hand-dominant man presented to the emergency department (ED) complaining of severe pain over his right clavicle with an obvious deformity and overlying ecchymosis. He reported the sudden onset of severe 10/10 in severity pain after he fell directly onto his right shoulder while playing soccer 1 day prior. He rated the pain currently at 9/10 in severity with any movement of shoulder and stated

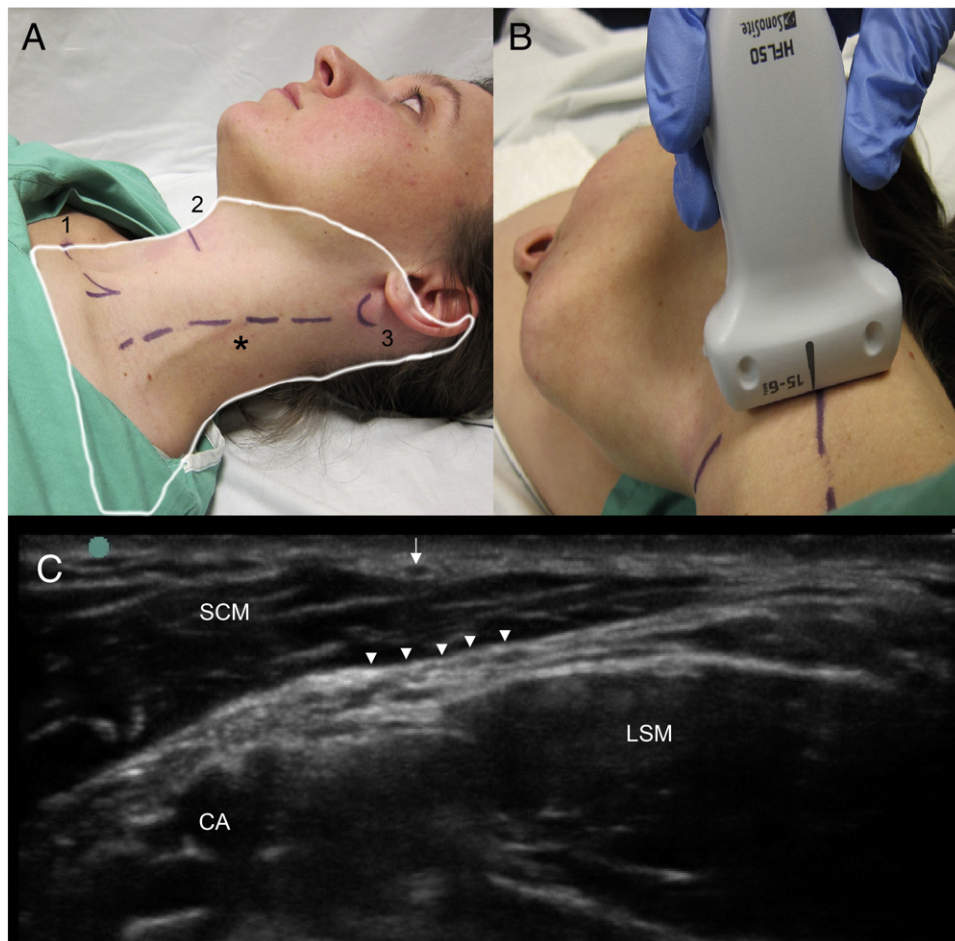


Fig. 2 A, The distribution of the cutaneous innervation of the SCP is outlined in white. Key surface landmarks include the (1) sternal notch, (2) superior pole of the thyroid cartilage, (3) the mastoid process, and (dashed line) the posterolateral border of the SCM muscle. The injection site is marked (*). B, Probe positioning for the in-plane approach in the lateral decubitus position. C, Survey ultrasound scan showing the tapering posterolateral border of the SCM, the carotid artery (CA), and the LSM. The greater auricular nerve can be identified as an hypoechoic structure above the SCM muscle (arrow) and the cervical plexus just deep to the muscle (arrow heads).

that he had been unable to sleep because of the pain. After radiographic confirmation of a midshaft angulated clavicle fracture, informed consent was obtained and an ultrasound-guided SCP block with 8 mL of 0.5% bupivacaine without epinephrine was performed using the aforementioned technique. When evaluated 20 minutes after completing the block, he rated his at pain 1 to 2/10 and was insensate to light touch over the lateral neck, ear lobe, and angle of mandible to cape of neck. At 24-hour telephone follow-up, the patient reported well-controlled pain allowing uninterrupted sleep. He stated that approximately 20 hours after the block was placed, he reported the return of moderate pain that was well controlled with oral analgesics.

4. Discussion

We present the first description of the use of an ultrasound-guided block of the SCP by an emergency

physician as part of an integrated approach to treatment of severe pain related to an acute clavicle fracture. In our experience, the SCP block is easy to perform, well tolerated, and most often quite successful in producing a dense sensory block for patients with clavicle fractures. For some patients with severe pain from clavicle fractures, the SCP block may be a useful adjunct to oral analgesics. With a long-acting anesthetic such as bupivacaine, the SCP may help the patient bridge to oral analgesics during the most painful acute phase of injury. In addition, the SCP block has been well described for anesthesia of the neck, submandibular area, and the ear lobe and is potentially useful for ED patients with ear lobe lacerations, submandibular abscesses, or injuries to the neck [3,4].

The major complication of the SCP block is inadvertent deep injection of local anesthetic leading to blockade of the deeper neural structures including the phrenic nerve, cervical plexus, brachial plexus, and the recurrent laryngeal nerve. Although no precise estimates of complication rates for the ultrasound-guided SCP block have been published, in our

Table 1 Characteristics of the ultrasound-guided SCP block

Characteristics of the ultrasound-guided SCP block	
Emergency care indications	Clavicle fractures, wounds, or painful procedures to the lateral neck and skin overlying the clavicles.
Technical considerations for ultrasound-guidance	With a high-frequency linear transducer, the target plane behind the sternocleidomastoid muscle is typically easy to identify. Lateral decubitus position with affected side up is optimal.
Positioning	Use an in-plane approach with a 21-25 gauge, 1.5-inch needle. In obese patients, a longer needle, such as a 3.5-inch spinal needle, may be necessary.
Needle approach	3-15 mL
Local anesthetic volume	Posterior border of the SCM muscle, external jugular vein, LSM, and the carotid artery
Important anatomy	Serious complications have not been reported. However, excessive local anesthetic volume or deep injection can potentially result in spread of local anesthetic to the phrenic nerve, recurrent laryngeal nerve, deep cervical plexus, and brachial plexus. Puncture of the external jugular vein and carotid artery.
Potential complications	

experience, this complication is easily avoided through standard block precautions, most importantly only injecting local anesthetic when there is direct visualization of the needle tip [10]. Whenever injecting local anesthetics, there is the risk of intravascular injection and resulting toxicity. Any

ED where local anesthetic is used should have staff who are trained and capable to manage acute toxicity including the use of lipid transfusions [11].

Our limited experience suggests that the ultrasound-guided SCP block is a potentially useful technique for emergency physicians treating pain related to clavicle fractures and injuries to ear lobe and lateral neck. Further prospective study of this promising technique is warranted.

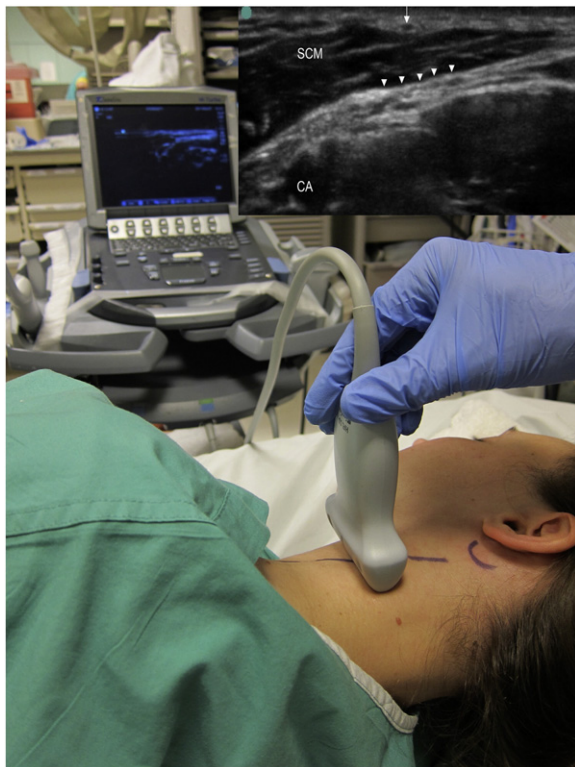

Fig. 3 Optimal patient and probe positioning for the lateral decubitus, in-plane approach ultrasound-guided SCP block provides an unobstructed view of the ultrasound machine seen in line with the operator and target structure. Inset shows survey sonogram. SCM, the carotid artery (CA), and the LSM.

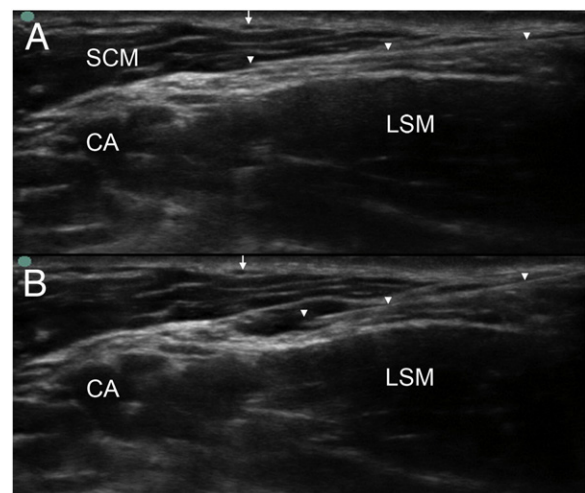


Fig. 4 A, Ultrasound-guided injection of local anesthetic begins with insertion of the needle 1 to 3 cm under the tapering posterolateral border of the SCM muscle just deep to the muscle belly but superficial to the deep fascia. The needle shaft is marked (arrowheads) with the needle tip beneath the greater auricular nerve (arrow). B, With injection of local anesthetic, the fascial plane should be observed in real time to distend. Generally, 8 to 10 mL is a sufficient volume. The local anesthetic will spread toward to carotid sheath but should remain superficial to the deep fascia if injected in the correct plane.

References

- [1] Arbona FL, Khabiri B, Norton JA. Ultrasound-guided regional anesthesia: a practical approach to peripheral nerve blocks and perineural catheters. Cambridge University Press; 2011.
- [2] Gray AT. Atlas of ultrasound-guided regional anesthesia. WB Saunders Co; 2009.
- [3] de Ramos EBA. Efficacy of anesthetic blockage of superficial branches of the cervical plexus. *Int J Odontostomat* 2008;2(1):77-81.
- [4] Shteif M, Lesmes D, Hartman G, Ruffino S, Laster Z. The use of the superficial cervical plexus block in the drainage of submandibular and submental abscesses—an alternative for general anesthesia. *J Oral Maxillofac Surg* 2008;66(12):2642-5.
- [5] Pandit JJ, Dutta D, Morris JF. Spread of injectate with superficial cervical plexus block in humans: an anatomical study {dagger}. *Br J Anaesth* 2003;91(5):733.
- [6] Nathe T, Tseng S, Yoo B. The anatomy of the supraclavicular nerve during surgical approach to the clavicular shaft. *Clin Orthop Relat Res* 2011;469(3):890-4.
- [7] Ebraheim NA, Whitehead JL, Alla SR, et al. The suprascapular nerve and its articular branch to the acromioclavicular joint: an anatomic study. *J Shoulder Elbow Surg* 2011;20(2):e13-7.
- [8] Choi DS, Atchabahian A, Brown AR. Cervical plexus block provides postoperative analgesia after clavicle surgery. *Anesth Analg* 2005;100(5):1542-3.
- [9] Marhofer P. Ultrasound guidance in regional anaesthesia: principles and practical implementation. 2nd ed. USA: Oxford University Press; 2010.
- [10] Pandit JJ, Satya-Krishna R, Gration P. Superficial or deep cervical plexus block for carotid endarterectomy: a systematic review of complications. *Br J Anaesth* 2007;99(2):159.
- [11] Manavi MV. Lipid infusion as a treatment for local anesthetic toxicity: a literature review. *AANA J* 2010;78(1):69-78.